

[Dashboard](#) / [2025 PREP ICU](#) / [Assessments](#) / [August](#)

Status Finished

Started Sunday, August 24, 2025, 9:15 AM

Completed Sunday, August 24, 2025, 9:19 AM

Duration 3 mins 48 secs

Points 6.00/6.00

Grade 100.00 out of 100.00

Feedback If you have satisfied the completion requirements for this assessment, you may proceed to claim your CME credit via the [AAP Transcript tool](#).

Question filtering

Filter by Question Topic ?

All

Filter by Question Status ?

All

Update

Clear

Question 1

Correct

1.00 points out of 1.00

[Comment](#)

A researcher began a double-blind, placebo-controlled randomized clinical trial at 3 intensive care units to evaluate the efficacy and safety of dexmedetomidine in reducing the occurrence of withdrawal symptoms in children receiving at least 5 days of opioid and benzodiazepine continuous infusions. A preplanned interim analysis allowed for early termination of the trial if the computed z statistic crossed the O'Brien-Fleming bounds, and possible modifications if the bounds were not crossed. The trial was terminated early based on analysis of the 2-stage group sequential design sample size.

Of the following, this type of clinical trial is

- A. adaptive ✓
- B. platform
- C. pragmatic
- D. traditional

Your answer is correct.

PREP Pearl(s)

- Adaptive clinical trial design allows for prospectively planned modifications to one or more aspects of the design based on accumulating data from trial participants.
- Preplanned modifications in adaptive trials include stopping the trial early for futility or efficacy, refining the sample size, abandoning treatment or doses, changing the allocation ratio of participants to trial arms, and focusing recruitment efforts on patients most likely to benefit.
- Pragmatic trials are designed to evaluate the effectiveness of interventions in real-life practice situations as opposed to explanatory trials that confirm a physiologic or clinical hypothesis and test whether an intervention is effective in optimal settings.

Critique

Traditional clinical trials follow a 3 step-process: design, implementation in accordance with the design, and analysis per a prespecified plan. Although straightforward, the inflexible design has several disadvantages. In contrast, adaptive clinical trial design incorporates prospectively planned modifications based on data accumulated from trial participants. This adaptive design also incorporates several modification strategies. Group sequential design allows early termination of the trial (in accordance with prespecified futility or efficacy criteria) during the planned interim analysis of collected trial data. Sample size estimation is performed in the planning stage; it requires information about the effect size, which is the magnitude of difference between the groups or the minimum effect an intervention must have to be considered clinically or practically significant. Effect size is often estimated from prior studies, experience, or judgment; it relies on assumptions, and it is often inaccurate. Using the results of interim analysis, sample size reestimation design allows researchers to modify the number of participants enrolled and thus avoid unnecessary enrollments.

Adaptive randomization also uses interim analysis so that researchers can change treatment-allocation randomization schemes over time. In the “pick-the-winner, drop-the-loser” design, researchers are permitted to make changes to treatment arms (eg, eliminating or bringing them in as determined by interim analyses). Ultimately, although they are more complex with potential sources of bias, adaptive trials usually require less time or fewer participants than nonadaptive trials.

A platform trial is a randomized and adaptive trial; it does not have a fixed end date. This kind of trial incorporates multiple interventions for a specific disease by allowing the elimination or incorporation of treatment arms over time. Unlike traditional intervention trials, which focus on the intervention or drug, a platform trial is disease-focused and open-ended, with new interventions being added, assessed, and removed with time through the adaptive process on the same trial platform and infrastructure.

Pragmatic trials evaluate how well interventions perform under real-world conditions, contrasting with explanatory trials that confirm a physiologic or clinical hypothesis. These trials test whether an intervention is effective in optimal settings. Pragmatic trials tend to enroll large numbers of participants from the whole target patient population using broad eligibility criteria. These trials are also designed with minimal data collection requirements and simple follow-up and produce results that can be generalized and applied to usual clinical settings.

The trial described in this vignette is an example of an adaptive clinical trial. There was a preplanned interim analysis of accumulating trial data with prespecified criteria (futility and efficacy) on the basis of which the trial was stopped. The interim analysis not only allowed for early termination of the trial (if the computed z statistic crossed the O'Brien-Fleming bounds) but also included other possible modifications if the bounds were not crossed. This demonstrates the use of preplanned modifications based on interim data.

Although traditional or conventional clinical trials may be designed with interim analyses and with prespecified rules for early termination, adaptive trials feature interim analyses with a priori planned adaptations. These adaptations include refinement of the sample size, discontinuing treatments or modifying doses, altering the allocation ratio of participants to trial arms, detecting participants most likely to benefit and concentrating on them, and stopping the trial early. The development of an adaptive design trial involves simulations that explore several scenarios, formulation of decision rules, and careful statistical analysis planning for simulations in the planning phase, for potential adaptations during interim analysis, and for the completed trial.

Suggested Reading(s)

- Gilholm P, Ergetu E, Gelbart B, et al. Adaptive clinical trials in pediatric critical care: a systematic review. *Pediatr Crit Care Med*. 2023;24(9):738-749. doi:[10.1097/PCC.0000000000003273](https://doi.org/10.1097/PCC.0000000000003273)
- Mondardini MC, Daverio M, Caramelli F, et al. Dexmedetomidine for prevention of opioid/benzodiazepine withdrawal syndrome in pediatric intensive care unit: interim analysis of a randomized controlled trial. *Pharmacotherapy*. 2022;42:145-153. doi:[10.1002/phar.2654](https://doi.org/10.1002/phar.2654)
- Schultz A, Saville BR, Marsh JA, Snelling TL. An introduction to clinical trial design. *Paediatr Respir Rev*. 2019;32:30-35. doi:[10.1016/j.prrv.2019.06.002](https://doi.org/10.1016/j.prrv.2019.06.002)
- Thorlund K, Haggstrom J, Park JJ, Milles EJ. Key design considerations for adaptive clinical trials: a primer for clinicians. *BMJ*. 2018;360:k698. doi:[10.1136/bmj.k698](https://doi.org/10.1136/bmj.k698)

Content Domain

- Research, principles

Learning Objectives

- Describe the fundamentals of adaptive clinical trials.

The correct answer is: adaptive

[View Peer Results](#)

Question 2

Correct

1.00 points out of 1.00

[Comment](#)

A 16-month-old infant with tonsillar and adenoid hypertrophy undergoes tonsillectomy and adenoidectomy at an outpatient surgical facility. They are extubated after the procedure but have significant respiratory distress requiring reintubation. After transfer to the pediatric intensive care unit, they are orally intubated with a 5.0 cuffed endotracheal tube. Chest radiography confirms appropriate positioning of the tip of the endotracheal tube in the mid trachea, with no pulmonary infiltrates. The infant is extubated the following day and is noted to have significant inspiratory stridor with retractions. They are given nebulized racemic epinephrine and started on intravenous (IV) dexamethasone. Nebulized racemic epinephrine administration is required every 2 to 4 hours, and the IV dexamethasone is given every 6 hours for the next 24 hours. The infant has improvement in their work of breathing, with stridor only with agitation, and the dexamethasone is discontinued.

The following day, the physician is called to the bedside. The infant has loud inspiratory stridor with significant supraclavicular and substernal retractions. Vital signs reveal a temperature of 35.9 °C, blood pressure of 94/42 mm Hg, heart rate of 186 beats/min, respiratory rate of 48 breaths/min, and oxygen saturation of 92% in room air. On examination, other than the stridor, the infant's lungs have fair air movement with no crackles or wheezes. The infant is afebrile with no cough or runny nose. Nebulized racemic epinephrine and IV dexamethasone are administered. Work of breathing and stridor improves with blood pressure 88/40 mm Hg, heart rate of 176 beats/min, respiratory rate 28 breaths/min, and oxygen saturation 98% in room air.

Of the following, the BEST next step is

- A. consult otolaryngology ✓
- B. intubation
- C. place a nasopharyngeal airway
- D. send a respiratory viral panel

Your answer is correct.

PREP Pearl(s)

- Extubation complications include laryngospasm, aspiration, sore throat, hoarseness, postextubation stridor, laryngeal or tracheal granulomas, vocal fold paralysis, or subglottic stenosis.
- Postextubation stridor is treated with nebulized racemic epinephrine and intravenous dexamethasone, and it may include helium-oxygen administration.
- In severe cases of postextubation requiring reintubation, the patient should be reintubated with a smaller size endotracheal tube.

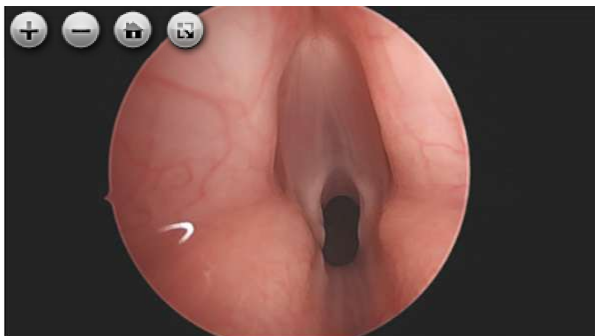
Critique

The infant in this vignette is having complications from an endotracheal intubation. Complications from tracheal intubation can occur at the time of intubation, during the maintenance period, or the extubation period. Immediate intubation complications include hypotension, dysrhythmias, hypoxia, emesis/aspiration, increased intracranial pressure, laryngospasm/bronchospasm, esophageal or mainstem bronchial intubation, dental/oral trauma, airway trauma, and cardiac arrest. Maintenance complications occur while intubated and receiving mechanical ventilation. These include atelectasis, ventilator associated pneumonia, endotracheal tube obstruction, lip or tongue ulceration, bronchospasm, and unplanned extubation.

Immediately following extubation, endotracheal complications include laryngospasm, aspiration, sore throat or hoarseness. Patients may also experience postextubation stridor, which occurs due to glottic or subglottic edema. Risk factors for postextubation stridor include young age, large endotracheal tube size, trauma, prolonged intubation, conditions associated with poor airway tone (such as trisomy 21), or excessive head or neck movement. Treatment consists of warmed humidified oxygen, nebulized racemic epinephrine, and IV dexamethasone and may include helium-oxygen administration. The lack of a leak around the endotracheal tube does not predict postextubation stridor. In severe cases, patients will require reintubation and should be intubated with a smaller endotracheal tube.

The infant in this vignette has stridor following extubation. The prolonged course of this patient's symptoms warrants an evaluation by otolaryngology, and may require flexible nasopharyngoscopy or rigid direct laryngoscopy and bronchoscopy. Evaluation by otolaryngology can reveal other complications of endotracheal intubation including laryngeal or tracheal granuloma or web (**Figure**), vocal cord paralysis, or subglottic stenosis. Granulomas can occur with direct trauma or ulcerations as the airway tissue attempts to heal. They can present as flaps of tissue that move with respiration or as valves that can occlude the airway. Vocal cord paralysis typically is seen unilaterally and occurs due to compression of the recurrent laryngeal nerve by the endotracheal tube putting pressure on the thyroid cartilage. These patients have a hoarse voice or low-pitched cry. Subglottic stenosis most commonly occurs in premature infants and young children intubated for prolonged periods.

Figure. Laryngeal web.



Courtesy of E. Reade

The correct response in this vignette is to consult otolaryngology. Intubation would not be the best next step, as the patient's work of breathing improved with nebulized racemic epinephrine and IV dexamethasone. Placement of a nasopharyngeal airway would not be correct as the patient is responsive to nebulized racemic epinephrine and IV dexamethasone. Sending a respiratory viral panel would not be helpful in a patient without signs or symptoms of an upper respiratory infection.

Suggested Reading(s)

- Divatia JV, Bhowmick K. Complications of endotracheal intubation and other airway management procedures. *Ind J Anaesth.* 2005;49(4):308-318. doi:[10.1097/00007611-198806000-00014](https://doi.org/10.1097/00007611-198806000-00014)

- Fuhrman BP, Zimmerman JJ. Airway management. In: *Pediatric Critical Care*. 5th ed. Elsevier; 2017:1766.
- Nishisaki A, Turner DA, Brown CA 3rd, et al. A national emergency airway registry for children: landscape of tracheal intubation in 15 PICUs. *Crit Care Med*. 2013;41(3):874-85. doi:[10.1097/ccm.0b013e3182746736](https://doi.org/10.1097/ccm.0b013e3182746736)
- Sood S, Ganatra HA, Perez Marques F, et al. Complications during mechanical ventilation: a pediatric intensive care perspective. *Front Med (Lausanne)*. 2023;10:1016316. doi:[10.3389/fmed.2023.1016316](https://doi.org/10.3389/fmed.2023.1016316)

Content Domain

- Critical Care, Medical Procedures, advanced

Learning Objectives

- Recognize the timing and complications of endotracheal intubation.

The correct answer is: consult otolaryngology

[View Peer Results](#)

Question 3

Correct

1.00 points out of 1.00

[Comment](#)

A 22-month-old infant with biliary atresia diagnosed at 3 months of age who subsequently underwent a Kasai procedure had been well until 2 weeks ago, when she had an upper respiratory tract infection. She is admitted to the pediatric intensive care unit with jaundice, several bloody stools, and increased sleepiness. After receiving 40 mL/kg of crystalloid, her hemoglobin level is 7.5 g/dL (75 g/L) and her platelet count is $0.08 \times 10^3/\mu\text{L}$ ($0.08 \times 10^9/\text{L}$). She has an international normalized ratio of 2.0, bilirubin level of 8 mg/dL (136.83 $\mu\text{mol/L}$), and serum ammonia level of 95 $\mu\text{g/dL}$ (67.83 $\mu\text{mol/L}$).

She is given intravenous vitamin K and administered rifaximin with lactulose via a nasogastric tube for her coagulopathy, and to reduce her ammonia level.

Of the following, the next BEST step in management of this patient's gastrointestinal hemorrhage is

- A. endoscopy with sclerotherapy
- B. octreotide infusion
- C. propranolol
- D. transjugular intrahepatic portosystemic shunt

Your answer is correct.

PREP Pearl(s)

- Octreotide is preferred over vasopressin for treatment of gastrointestinal hemorrhage due to fewer adverse effects.
- Endoscopy with sclerotherapy provides definitive evaluation of the source of bleeding and therapeutic intervention.
- Evaluation for liver transplantation should be part of any pediatric hospitalization for gastrointestinal hemorrhage.

Critique

Octreotide is a synthetic somatostatin analogue; it shares many properties with vasopressin but has fewer adverse effects. Octreotide infusions are effective in reducing portal hypertension and decreasing the likelihood of further bleeding. Octreotide reduces splanchnic blood flow through vasoconstriction. The subsequent reduction in flow helps reduce portal pressure. The reduction of portal pressure along with the induction of platelet aggregation helps reduce the likelihood of further bleeding in patients with gastrointestinal hemorrhage. Medical management with octreotide is the first step for patient stabilization.

Once the patient has been stabilized with octreotide, then endoscopy with sclerotherapy is the preferred method to prevent bleeding when the infusion is discontinued. Endoscopy is beneficial because the extent of varices can be documented and sites that appear likely to bleed can be sclerosed. A Cochrane Review could not find any benefit to band ligation of varices, but there was limited evidence to evaluate the efficacy of this therapy. Sclerotherapy is currently preferred over banding in pediatrics.

Nonselective β -blockers, such as propranolol, are beneficial in decreasing gastrointestinal hemorrhage. The proposed mechanism of action is decreased heart rate and cardiac output. The reduction in cardiac output helps decrease portal resistance and reduce the chance of bleeding. However, not all patients have sufficient reduction in their heart rate to decrease the risk of gastrointestinal hemorrhage. Administration of propranolol in a young child with ongoing bleeding could compromise cardiac output and would not be the first-line therapy in this case.

Transjugular intrahepatic portosystemic shunts are placed in older children and adults who are not candidates for liver transplantation or as a temporizing measure. In infants and young children who have portal hypertension due to fibrosis and cirrhosis of the liver, the preferred treatment is liver transplantation. In this vignette, the child would likely be evaluated for transplantation during the admission or at a later date, possibly via a living-related donor. The case described above emphasizes the need for close monitoring by the hepatology team to ensure native liver function is preserved for as long as possible and to develop options for transplantation.

Biliary atresia affects 1 in 3,500 to 20,000 live births worldwide, with higher prevalence in Asia and French Polynesia. In the United States, Europe, and Canada, it affects 1 in 20,000 live births, with higher rates seen in premature Black and Asian infants. In biliary atresia, the bile ducts do not form properly, but it is unclear whether this is due to a genetic mutation, environmental agent, autoimmune response, or infection because all these origins have been linked to cases of biliary atresia. The resultant defect in the bile ducts results in jaundice, poor feeding, and weight loss. If biliary atresia is recognized early and the child undergoes the Kasai procedure before 2 months of age, then the procedure will be successful in more than 80% of the cases.

The Kasai procedure connects the small intestine directly to the portion of the liver that produces bile (porta hepatis). The procedure allows the damaged ducts to be bypassed and provide drainage for the bile. If, however, jaundice goes unrecognized and the child undergoes the Kasai procedure after 2 months of age, then the success rate decreases rapidly. Jaundice may be more difficult to diagnose in children with darker skin tones, so it is important to recognize other factors, such as poor weight gain or increased abdominal girth, that may be indicative of biliary atresia.

When the procedure is performed in a child older than 2 months, fibrosis and resultant cirrhosis of the liver are more likely, which raises the pressure in the portal system. The normal pressure in the portal system is 5 to 10 mm Hg. When the pressure is elevated due to cirrhosis, then there is increased likelihood of varices and ascites. Ascites are less common in infants than in older children or adults, but infants are at equivalent risk of varices. These varices are then at increased risk of bleeding, especially when there is additional stress on the child, such as increased abdominal pressure from coughing or sneezing during a respiratory infection or increased cardiac output during a febrile illness.

Suggested Reading(s)

- Cifuentes LI, Gattini D, Torres-Robles R, Gana JC. Band ligation versus sham or no intervention for primary prophylaxis of oesophageal variceal bleeding in children and adolescents with chronic liver disease or portal vein thrombosis. *Cochrane Database Syst Rev*. 2021;1(1):CD011561. doi:[10.1002/14651858.CD011561.pub2](https://doi.org/10.1002/14651858.CD011561.pub2)
- Mileti E, Rosenthal P. Management of portal hypertension in children. *Curr Gastroenterol Rep*. 2011;13(1):10-6. doi:[10.1007/s11894-010-0151-y](https://doi.org/10.1007/s11894-010-0151-y)
- Oliveira APP, Ferreira AR, Fagundes EDT, et al. Endoscopic prophylaxis and factors associated with bleeding in children with extrahepatic portal vein obstruction. *J Pediatr (Rio J)*. 2020;96(6):755-762. doi:[10.1016/j.jped.2019.08.010](https://doi.org/10.1016/j.jped.2019.08.010)
- Shneider BL, Abel B, Haber B, et al; Childhood Liver Disease Research and Education Network. Portal hypertension in children and young adults with biliary atresia. *J Pediatr Gastroenterol Nutr*. 2012;55(5):567-573. doi:[10.1097/MPG.0b013e31826eb0cf](https://doi.org/10.1097/MPG.0b013e31826eb0cf)

Content Domain

- Critical Care, Liver Failure

Learning Objectives

- Recognize the factors that lead to portal hypertension in children.
- Identify which therapies are appropriate for acute management of gastrointestinal hemorrhage and which therapies will be needed after stabilization

The correct answer is: octreotide infusion

[View Peer Results](#)

Question 4

Correct

1.00 points out of 1.00

[Comment](#)

A 6-year-old child has been admitted with volume overload, elevated creatinine levels, and hypertension. The child had been well until he developed a cough, fever, and sore throat 4 days ago. The parent reports that the child's face began to look puffy 2 days ago, and now his feet are also swollen. They also report that their son's urine "looked like soda."

The child had been taken to his primary physician but they referred them to the emergency department for markedly elevated blood pressure. The child is admitted to the intensive care unit for blood pressure and fluid overload management. On physical examination, a purpuric rash is also noted on his ankles.

Of the following, the laboratory findings that would BEST support a presumptive diagnosis are

- A. antineutrophil cytoplasmic antibodies present ✓
- B. antistreptolysin titer <70 IU/mL
- C. elevated C3 level
- D. normal C4 level

Your answer is correct.

PREP Pearl(s)

- Elevation of antineutrophil cytoplasmic autoantibody titers will be positive in acute crescentic glomerulonephritis, and should prompt urgent renal biopsy.
- The majority of poststreptococcal glomerulonephropathies respond to diuretics and antihypertensive medication without the need for dialysis.
- Lupus and IgA nephropathy can be distinguished by measuring C3, C4, and dsDNA titers

Critique

Acute glomerulonephritis can have many etiologies. The patient in the vignette has classic findings of an IgA nephropathy. The combination of edema, hematuria causing the urine to look dark, hypertension, and purpura associated with an intercurrent illness are helpful clues to this diagnosis. A purpuric rash helps differentiate this presentation from that of systemic lupus. The presence of antineutrophil cytoplasmic antibodies is crucial for the identification of IgA nephropathy as the underlying disease.

IgA nephropathy can present with similar signs and symptoms as post-streptococcal or acute crescentic glomerulonephritis. Timely identification of acute crescentic glomerulonephritis is important; rapid decline in renal function may result in chronic kidney disease or dialysis dependence that is irreversible without early intervention. These interventions often include high-dose corticosteroids and cyclophosphamide to prevent further immune mediated kidney damage. The laboratory finding that best distinguishes these 2 etiologies is the antineutrophil cytoplasmic autoantibody (ANCA) test, which will have positive results in acute crescentic glomerulonephritis form of IgA nephropathy and negative results in poststreptococcal glomerulonephritis.

Antineutrophil antibodies are classified as either perinuclear antineutrophil antibodies (P-ANCA) or PR3 antineutrophil antibodies (C-ANCA). Antineutrophil antibodies attack proteins within white blood cells and result in a variety of autoimmune diseases. The presence of antineutrophil antibodies and the presence of vasculitis symptoms involving pulmonary or gastrointestinal systems should raise concern for acute crescentic glomerulonephritis. This form of glomerulonephritis causes sclerosis and results in loss of kidney function over weeks to months if the inflammatory response is not attenuated. Timely intervention will halt glomerular loss and decline in kidney function. Other conditions to also be considered would include systemic lupus, post-staphylococcal infection, and IgA nephropathy. Medications can also trigger ANCA-associated vasculitis but would be unlikely in an otherwise healthy child.

Poststreptococcal glomerulonephritis as seen in the patient in this vignette is the most common glomerular disease in early childhood. It is classified as an immune-complex (type 3) hypersensitivity reaction that follows a recent group A *Streptococcus* infection. The classic triad of edema, dark urine, and hypertension typically occur 1 to 2 weeks after a throat infection or 4 to 6 weeks following impetigo. The proposed mechanism is that nephrogenic strains of group A *Streptococcus* elicit the formation of antibody-antigen complexes within the glomeruli, which cause inflammation and damage. The antistreptolysin (ASO) titer is elevated in recent streptococcal infections with levels greater than 70 IU/mL in children younger than 5 years and greater than 200 IU/mL in older children. These levels will then slowly decline a month after the initial infection but remain elevated for up to 6 months after the initial rise. A titer level less than 70 IU/mL would be interpreted as a negative result for recent infection. Unless there was a documented group A streptococcal infection in the last month, the diagnosis of poststreptococcal glomerulonephritis would be highly unlikely.

Fortunately, most cases of poststreptococcal glomerulonephritis resolve without intervention. In those cases presenting with fluid overload and hypertension, the use of diuretics to treat volume overload and antihypertensives is often sufficient until the inflammation resolves and renal function returns to normal. Long-term studies have not found any prolonged renal effect from childhood poststreptococcal glomerulonephritis but have found effects in adults diagnosed with this disease.

Complement levels are used to determine if IgA nephropathy or systemic lupus should also be considered as the cause of glomerulonephritis. Systemic lupus classically has low C3 and C4 levels along with positive double-stranded DNA titers. In contrast, IgA nephropathy typically has normal or elevated C3 and C4 levels. Although there are cases where C3 can be low and C4 normal in IgA nephropathy these patterns typically portend a more difficult clinical course. In all of these cases, renal biopsy with immunofluorescence staining and electron microscopy will be necessary to make a firm diagnosis. However, in those cases that are ANCA positive, the biopsy should be performed quickly so that high-dose corticosteroids can be started and then cyclophosphamide or other immunomodulatory agents can be decided on once the biopsy is complete and the pathology has been reviewed.

Suggested Reading(s)

- Mohamed ON, Ibrahim SA, Saleh RK, et al. Clinicopathological characteristics and predictors of outcome of rapidly progressive glomerulonephritis: a retrospective study. *BMC Nephrol.* 2024;25(1):103. doi:[10.1186/s12882-024-03532-y](https://doi.org/10.1186/s12882-024-03532-y).
- Moroni G, Ponticelli C. Rapidly progressive crescentic glomerulonephritis: early treatment is a must. *Autoimmun Rev.* 2014;13(7):723-9. doi:[10.1016/j.autrev.2014.02.007](https://doi.org/10.1016/j.autrev.2014.02.007)
- Piyaphanee N, Ananboontarick C, Supavekin S, Sumboonnanonda A. Renal outcome and risk factors for end-stage renal disease in pediatric rapidly progressive glomerulonephritis. *Pediatr Int.* 2017;59(3):334-341. doi:[10.1111/ped.13140](https://doi.org/10.1111/ped.13140)

Content Domain

- Renal, Glomerular Disorders

Learning Objectives

- Differentiate between the etiologies of glomerulonephritis that require rapid identification, biopsy and treatment

The correct answer is: antineutrophil cytoplasmic antibodies present

[View Peer Results](#)

Question 5

Correct

1.00 points out of 1.00

[Comment](#)

A 3-year-old child requiring intubation is admitted to the pediatric intensive care unit for vomiting and altered mental status. After 48 hours with no sedation, the patient's neurologic status has not improved. Vital signs are otherwise within normal limits. The child's medical history is notable for developmental delay and seizure disorder. Head computed tomography was performed, the results show no intracranial pathology. A serum phenytoin level was 80 mg/L (317.44 μ mol/L) (therapeutic range, 10-20 mg/L). An albumin level was 2.8 g/dL (28 g/L).

Of the following, the MOST effective method at reversing this patient's condition is

- A. extracorporeal photopheresis
- B. hemodialysis ✓
- C. lipid infusion
- D. systemic alkalization

Your answer is correct.

PREP Pearl(s)

- The degree of protein-binding affects a drug's distribution and elimination.
- Hemodialysis may provide effective clearance of the unbound or free fraction of a protein-bound substance.

Critique

Phenytoin is an antiepileptic drug with a narrow therapeutic window. The supratherapeutic level of phenytoin in the child in the vignette suggests phenytoin toxicity as the cause of their symptoms. At supratherapeutic levels, phenytoin can cause nystagmus, ataxia, nausea, and vomiting, with toxic concentration causing coma and seizures. Rarely, high levels of phenytoin can also cause cardiac toxic effects.

Phenytoin is extensively bound to plasma proteins, with the unbound or free form being responsible for its clinical effects. Phenytoin is predominantly metabolized by the CYP enzyme system to inactive metabolites, and its apparent elimination half-life is approximately 22 hours. In overdose, the half-life increases, which is why massive overdoses may lead to prolonged toxic effects. There is no effective antidote available to reverse phenytoin's effects.

Although supportive care is the first-line recommendation for phenytoin poisoning, extracorporeal toxin removal may be considered in severe cases, such as the one described in the vignette. Theoretically, due to phenytoin's extensive binding to plasma proteins, hemoperfusion and therapeutic plasma exchange (TPE) would be the most effective way of removing phenytoin from the vascular compartment. However, TPE's rate of removal is slow, only removing 5% to 10% of a total body load during a single 2 to 3 hours of exchange. Although initial clearances with hemoperfusion are higher than with TPE, clearance is subsequently limited by the saturation of the charcoal column, which usually occurs within 2 hours. Hemodialysis with high-efficiency

filters can provide a much higher clearance, especially in patients with conditions that reduce protein binding (eg, hypoalbuminemia and kidney disease). Although hemodialysis is not the most effective way of removing protein-bound toxins, in phenytoin toxicity there is enough free phenytoin in the plasma able to be removed during dialysis. Some studies have investigated adding albumin in the dialysate for better clearance, but there are conflicting results on whether this substantially enhances the removal of phenytoin.

Although most evidence regarding the use of hemodialysis in phenytoin poisoning is case reports and studies, the EXTRIP (Extracorporeal Treatments in Poisoning) Workgroup recommends intermittent hemodialysis as the method with the best sustainable clearance. Given the intensive resources required for extracorporeal toxin removal, hemodialysis is suggested when prolonged coma is present or expected, especially because initiation of hemodialysis may necessitate mechanical ventilation and intensive care unit stays.

Systemic alkalinization therapy is not useful in increasing the clearance of phenytoin. Similarly, lipid infusion does not decrease phenytoin levels. Lipid infusion is commonly used as a “sink” in local anaesthetic systemic toxic effects and a potential antidote for other lipophilic drug poisoning. Extracorporeal photopheresis is a leukapheresis-based therapy that involves ex vivo treatment of leukocytes with 8-methoxypsoralen and UV-A irradiation, which then are reinfused back to the body. It has been used in the treatment of cutaneous T-cell lymphoma as well as second-line treatment for steroid-refractory graft vs host disease.

Suggested Reading(s)

- Anseeuw K, Mowry JB, Burdmann EA, et al. Extracorporeal treatment in phenytoin poisoning: systematic review and recommendations from the EXTRIP (Extracorporeal Treatments in Poisoning) Workgroup. *Am J Kidney Dis.* 2016;67(2):187-197. doi:[10.1053/j.ajkd.2015.08.031](https://doi.org/10.1053/j.ajkd.2015.08.031)
- Ghannoum M, Troyanov S, Ayoub P, Lavergne V, Hewlett T. Successful hemodialysis in a phenytoin overdose: case report and review of the literature. *Clin Nephrol.* 2010;74(1):59-64. doi:[10.5414/cnp74059](https://doi.org/10.5414/cnp74059)
- Harbord N. Common toxidromes and the role of extracorporeal detoxification. *Adv Chronic Kidney Dis.* 2020;27(1):11-17. doi:[10.1053/j.ackd.2019.08.016](https://doi.org/10.1053/j.ackd.2019.08.016)

Content Domain

- Pharmacology, Pharmacokinetics

Learning Objectives

- Review common drugs that are highly bound by protein
- Understand the mechanism and challenges of toxin removal using extracorporeal techniques

The correct answer is: hemodialysis

[View Peer Results](#)

Question 6

Correct

1.00 points out of 1.00

[Comment](#)

A 14-year-old adolescent with a history of relapsed acute lymphoblastic leukemia (ALL) is evaluated in the pediatric intensive care unit for a 2-week history of worsening headache, nausea, and photophobia. During the past 3 days, his family noticed increasing confusion, irritability, and intermittent fevers. He has no history of seizures.

On admission, the patient is febrile (temperature, 39.2 °C), tachycardic (heart rate, 145 beats/min), and lethargic, with a Glasgow Coma Scale score of 9 (eye opening, 2; verbal response, 2; and motor response, 5). His pupils are equal and reactive, but fundoscopic examination reveals bilateral papilledema. Motor examination shows symmetric but reduced spontaneous movement, with no focal deficits.

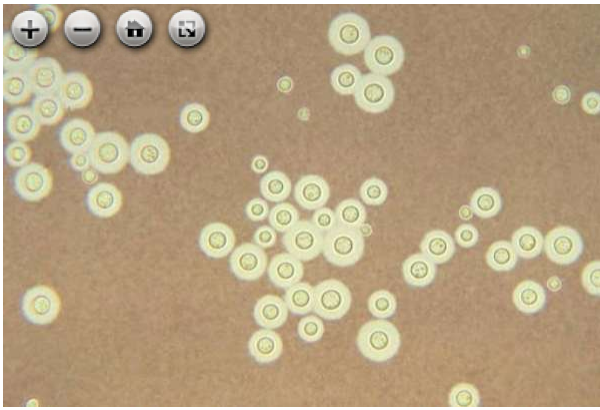
Laboratory data are shown:

Laboratory Test	Result	Reference Range
White blood cells	200/ μ L (0.2×10^9 /L)	4,500-11,000/ μ L (4.5 - 11.0×10^9 /L)
Platelets	22×10^3 / μ L (22×10^9 /L)	150 - 400×10^3 / μ L (150 - 400×10^9 / μ L)
C-reactive protein	8.20 mg/dL (82 mg/L)	<0.50 mg/dL (<5 mg/L)
Creatinine	0.6 mg/dL (53.04 μ mol/L)	0.5-1.0 mg/dL (44.20-88.40 53.04 μ mol/L)
Sodium	129 mEq/L (129 mmol/L)	135-145 mEq/L (135-145 mmol/L)

Head computed tomography shows no evidence of mass effect or hydrocephalus but confirms moderate cerebral edema, without concern for herniation. An intracranial pressure monitoring device is placed, and lumbar puncture is performed with the following cerebrospinal fluid (CSF) findings:

Parameter	Result	Reference Range
Opening pressure	42 cm H ₂ O	<20 cm H ₂ O
White blood cells	56/ μ L (90% lymphs)	0-5/ μ L
Protein	180 mg/dL	15-45 mg/dL
Glucose	18 mg/dL	40-70 mg/dL

India ink staining of CSF specimens is performed, and a representative image is shown (**Figure**). The results of additional CSF analyses and blood cultures are pending.



Of the following, the next BEST step in management is

- A. amphotericin plus flucytosine ✓
- B. dexamethasone
- C. therapeutic cerebrospinal fluid drainage
- D. voriconazole monotherapy

Your answer is correct.

PREP Pearl(s)

- Amphotericin B and flucytosine remain the standard induction therapies for cryptococcal meningitis, offering rapid fungicidal effects and improved safety compared with conventional formulations. Liposomal formulation of amphotericin can be used for those with renal insufficiency or intolerant to amphotericin due to adverse effects.
- Voriconazole is effective against *Aspergillus* and some *Candida* species, but is not recommended as monotherapy for cryptococcal meningitis.
- Intracranial pressure management is critical to prevent neurologic complications, but aggressive cerebrospinal fluid drainage should be avoided in cryptococcal meningitis.

Critique

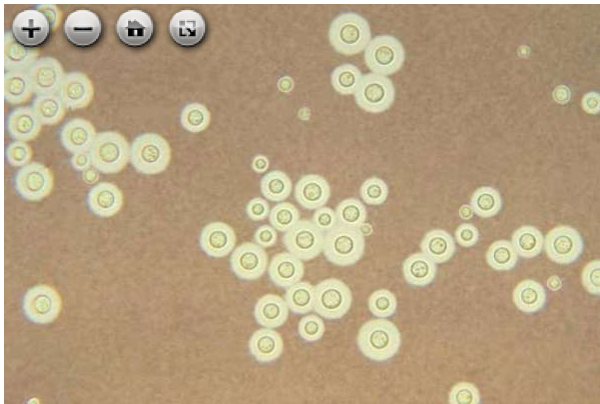
Cryptococcus neoformans is a yeast found worldwide in the environment that is commonly associated with bird droppings (especially pigeons), soil, and decaying wood. It is responsible for 95% of cryptococcal infections. Although it is generally harmless to healthy individuals, it can cause life-threatening infections, such as severe meningitis or meningoencephalitis in immunocompromised patients, such as those receiving chemotherapy, immunosuppression for solid organ transplantation, or long-term corticosteroid therapy. Additionally, patients with HIV also have increased susceptibility.

Once inhaled, *C. neoformans* spreads hematogenously, with a predilection for the central nervous system due to its ability to cross the blood-brain barrier. The presence of several virulence factors make clearance by the innate immune system challenging, often leading to persistent infection. The infection manifests as meningoencephalitis, characterized by elevated intracranial pressure (ICP), giving rise to symptoms such as headache, nausea, and photophobia. Patients with elevated ICP may have papilledema on a fundoscopic examination. Other symptoms may include lethargy, confusion, and cranial nerve deficits due to meningeal

involvement. Moreover, patients with more advanced infections may present with, or develop, obtundation and seizures. The cause of the ICP elevation is cryptococcal polysaccharides blocking the arachnoid villi, thereby compromising cerebrospinal fluid (CSF) reabsorption, leading to hydrocephalus.

Key data obtained often include an elevated opening pressure during lumbar puncture (>20 cm H₂O) and CSF analysis demonstrating lymphocytic pleocytosis, elevated protein level, and low glucose levels. Diagnostic assays include India Ink staining of CSF that can show encapsulated yeast (**Figure**). Serum cryptococcal antigen (CrAg) can also aid diagnosis in systemic infection or cases in which lumbar puncture cannot be performed. Culture of both CSF and blood may confirm diagnosis but is often slow to result. In cases in which CSF results are inconclusive, polymerase chain reaction can offer a definitive diagnosis by detecting fungal DNA with high sensitivity and specificity.

Figure. *Cryptococcus neoformans* infections (cryptococcosis). This photomicrograph depicts *C. neoformans* using a light India ink staining preparation.



Courtesy of the Centers for Disease Control and Prevention.

Per clinical practice guidelines, pharmacotherapies are delineated into induction and consolidation phases, followed by maintenance therapy. For pediatric patients without HIV who have not undergone transplant, amphotericin B plus flucytosine is the first-line therapy for cryptococcal meningitis in the induction phase, followed by fluconazole during the consolidation and maintenance phases of therapy. Amphotericin B binds ergosterol in the fungal cell membrane, creating pores that cause ion leakage and cell death. Of note, liposomal formulations of amphotericin can be used for patients who have renal insufficiency or for patients intolerant of amphotericin due to adverse effects. Flucytosine is coadministered for synergy with amphotericin B to improve fungal clearance. The induction phase typically lasts 2 weeks and aims to rapidly reduce fungal burden. This is followed by fluconazole for 8 weeks to prevent recurrence.

Voriconazole monotherapy is effective against *Aspergillus* and some *Candida* species but is not recommended as monotherapy for cryptococcal meningitis. It has limited evidence for use during the induction phase and is not as effective as amphotericin B for rapid fungal clearance. Voriconazole may be considered in patients who cannot tolerate amphotericin B, but its penetration into the central nervous system is inferior in this setting.

Elevated ICP is common in cryptococcal meningitis due to increased CSF production and reduced absorption. Although therapeutic lumbar punctures are a key part of ICP management, first-line therapy is not CSF evacuation; moreover, aggressive or rapid drainage can precipitate brain herniation due to sudden pressure shifts. Controlled CSF removal is recommended, aiming to reduce ICP gradually to 20 cm H₂O or less during multiple sessions. Literature suggests that the safe maximum volume of CSF that can be drained at one lumbar puncture is unclear, but up to 30 mL is frequently removed with the pressure checked after each 10 mL is removed.

Administering dexamethasone for cerebral edema is contraindicated in cryptococcal meningitis, because it may impair immune-mediated fungal clearance. Steroids can be considered in cases of immune reconstitution inflammatory syndrome or severe immune reconstitution inflammatory syndrome–related complications.

Suggested Reading(s)

- Abassi M, Boulware DR, Rhein J. Cryptococcal meningitis: diagnosis and management update. *Curr Trop Med Rep*. 2015;2(2):90-99. doi:[10.1007/s40475-015-0046-y](https://doi.org/10.1007/s40475-015-0046-y).
- Alanazi AH, Adil MS, Lin X, et al. Elevated intracranial pressure in cryptococcal meningoencephalitis: examining old, new, and promising drug therapies. *Pathogens*. 2022;11(7):783. doi:[10.3390/pathogens11070783](https://doi.org/10.3390/pathogens11070783)
- Perfect JR, Dismukes WE, Dromer F, et al. Clinical practice guidelines for the management of cryptococcal disease: 2010 update by the Infectious Diseases Society of America. *Clin Infect Dis*. 2010;50(3):291-322. doi:[10.1086/649858](https://doi.org/10.1086/649858)
- Williamson PR, Jarvis JN, Panackal AA, et al. Cryptococcal meningitis: epidemiology, immunology, diagnosis and therapy. *Nat Rev Neurol*. 2017;13(1):13-24. doi:[10.1038/nrneurol.2016.167](https://doi.org/10.1038/nrneurol.2016.167)

Content Domain

- Infectious Diseases, Central Nervous System Infections

Learning Objectives

- Recognize the diagnostic and management challenges in CNS fungal infections, particularly cryptococcal meningitis
- Understand the pharmacologic principles and limitations of antifungal agents in CNS infections
- Manage elevated intracranial pressure in patients with cryptococcal meningitis while avoiding complications

The correct answer is: amphotericin plus flucytosine

[View Peer Results](#)